

Treatment of facial post-burn hyperpigmentation using micro-plasma radiofrequency technology

Lian-Zhao Wang · Jin-Ping Ding · Ming-Yong Yang ·
Dian-Wei Chen · Bo Chen

Received: 27 February 2014 / Accepted: 28 August 2014
© Springer-Verlag London 2014

Abstract Management of facial post-burn hyperpigmentation is a common and challenging problem for dermatologists and plastic surgeons. The recent development of micro-plasma radiofrequency technology, which allows precise and rapid treatment with controlled thermal injury, can be an effective treatment of post-burn hyperpigmentation. This study aimed to evaluate the effectiveness and complications of micro-plasma radiofrequency treatment of post-burn hyperpigmentation. The study included 35 patients with Fitzpatrick skin type III or IV and facial post-burn hyperpigmentation. Patients received three to five treatments at 8-week intervals. A roller tip was used with the power setting at 60–90 W, and 3–4 passes were made in different directions. The degree of improvement and complications were recorded. Improvement of hyperpigmentation was evaluated by patient self-assessment and by plastic surgeons who compared digital photographs taken before treatment and 2 months after the last treatment. The results showed that post-burn hyperpigmentation responded favorably to micro-plasma radiofrequency treatment with very few complications. The average pain score using a visual analog scale from 0 to 10 was 6.7 ± 0.7 . After a series of treatments, 32 of the 35 patients had achieved a >51 % improvement of their hyperpigmentation, and 3 patients had achieved a fair improvement. The mean score for improvement of hyperpigmentation was 4.28. Patient self-

evaluations indicated good satisfaction with the cosmetic outcomes, and some softening of the scars. Micro-plasma radiofrequency technology is appropriate, effective, and safe for the treatment of facial post-burn hyperpigmentation, and provides a promising noninvasive treatment for superficial facial injuries.

Keywords Post-burn hyperpigmentation · Facial · Micro-plasma · Radiofrequency

Introduction

In dark-skinned individuals, superficial partial-thickness burns that are not properly treated often result in permanent hyperpigmentation and superficial scarring. Such hyperpigmentation may impact negatively on the patient's social interactions and quality of life, especially when it occurs on the face, which may become a bigger problem than the physical damage caused by the scar. Hyperpigmentation is often the main reason for consultation with a dermatologist or plastic surgeon to receive medical treatments.

Many topical agents, such as bleaching creams, are available to treat hyperpigmentation. These topical agents can interfere with the pigmentation process at different levels. The traditional gold standard treatment for hyperpigmentation is hydroquinone, which acts by inhibiting the activity of tyrosinase. However, bleaching creams are not effective for the treatment of remnant scar tissue and are associated with adverse effects such as “hydroquinone halo,” irritation, erythema, post-inflammatory hyperpigmentation, and exogenous ochronosis [1–3].

Light-based technologies such as the 1,064-nm Q-switched Nd: YAG laser, intense pulsed light laser, and carbon dioxide laser have recently been used for the treatment of hyperpigmentation or scars. These therapies are based on selective

Lian-Zhao Wang and Jin-Ping Ding contributed equally in this study.

L.-Z. Wang · J.-P. Ding · M.-Y. Yang · B. Chen (✉)
Department of Plastic and Reconstructive Surgery, Plastic Surgery Hospital, Chinese Academy of Medical Sciences & Peking Union Medical College, No. 33 Ba-Da-Chu Road, Shi Jing Shan District Beijing 100144, People's Republic of China
e-mail: chenboys@hotmail.com

D.-W. Chen
Shantou Central Hospital, Sun Yat-sen University, Shantou, Guangdong 515000, People's Republic of China

photothermolysis targeting melanin or water in the epidermis, but the success rate is variable and operator dependent. Moreover, hypopigmentation, post-inflammatory hyperpigmentation, and even scarring may occur in spite of careful use of these therapies [4–7]. The treatment of hyperpigmentation in superficial post-burn scars is therefore a common and challenging problem for dermatologists and plastic surgeons, especially in patients with darker skin.

Micro-plasma radiofrequency treatment has recently been used for minimally ablative fractional resurfacing of scars. The radiofrequency energy acts on nitrogen gas to form a grid of high-energy foci called plasma sparks, resulting in a portion of the atoms being ionized and applied evenly onto the skin. This causes mild ablation of the epidermis with formation of micro-channels, heating of the dermis and subcutaneous tissues by the powerful radiofrequency energy with minimal thermal injury to the surrounding tissues. In the porcine skin model reported by Halachmi et al. [8], the thermal energy extended to a depth of 100–150 μm and a diameter of 80–120 μm , depending on the radiofrequency power and pulse duration. Micro-plasma radiofrequency treatment results in controlled thermal modification of the underlying dermis, with new collagen synthesis and collagen remodeling. Some researchers have reported successful use of this treatment for acne scars [8, 9], facial rhytids [8, 10], traumatic scars [11], and mesh skin grafted scars [12], with minimal downtime and few adverse effects. This report introduces a new treatment method for post-burn hyperpigmentation and reports our experience with this treatment.

Patients and methods

Patients

The study group included 35 healthy Asian patients (13 males, 22 females) with an age range of 6–40 years and Fitzpatrick skin type III or IV [13]. The patients all had a history of facial superficial partial-thickness burns resulting in superficial scarring and permanent hyperpigmentation ranging from pale brown to deep brown. Patients were excluded if they had undergone previous dermabrasion or laser treatment, had used isotretinoin within the past 6 months, or had a history of mental illness, keloid scarring, impaired immune function, a cardiac pacemaker or other metal implant near the site of hyperpigmentation, or concomitant pregnancy. The study period was June 2012 to July 2013.

Methods

The study was performed in accordance with the guidelines of the 1964 Declaration of Helsinki. All patients gave written

treatment of informed consent, including permission for the use of digital photographs. After cleaning the facial skin, the area being treated was anesthetized with 10 % lidocaine cream (Qinghua Pharmaceuticals, Beijing, China) under plastic wrap for 60–90 min. Each patient underwent three to five treatments at 8-weekly intervals using the micro-plasma radiofrequency device (Alma Lasers, Israel). A roller tip was used with the power setting at 60–90 W, and 3–4 passes were made in different directions. Immediately after the treatment, patients were asked to rate their pain level on a visual analog scale from 0 to 10.

Patients were given comprehensive instructions regarding post-procedure care after each treatment. Sterile saline and erythromycin eye ointment were applied to the treated area daily for 6 days to prevent infection. Patients were instructed to apply sunscreen lotion (sun protection factor ≥ 30) to the treated area and to avoid physical trauma to the skin, such as scratching or rubbing. Patients were asked about any discomfort on the day of surgery and at subsequent follow-up visits.

Assessment

For each patient, improvement of hyperpigmentation was assessed by comparison of the difference in color between the burnt skin and the adjacent normal skin on pre- and post-treatment photographs. Standardized digital photographs using the same patient positioning, distance, lighting, and camera settings were obtained before treatment and 2 months after the final treatment. The reduction of hyperpigmentation and side effects were assessed for each patient by the same two experienced plastic surgeons who were blinded to the patient details and treatment method. Two months after the last treatment, patients were asked to evaluate their improvement using the same categories and scales.

Improvement of hyperpigmentation was graded using the following scale: excellent (76–100 % improvement, 5), good (51–75 % improvement, 4), fair (26–50 % improvement, 3), poor (1–25 % improvement, 2), and none (0 % improvement, 1).

Table 1 Complications ($n=35$)

VAS pain score (0–10), mean \pm SD	6.7 \pm 0.7
Epithelization time (days), mean \pm SD	7.0 \pm 1.2
Infections	0
Hyperpigmentation	0
Hypopigmentation	0
Worsening of scarring	0

Table 2 Assessment of improvement of post-burn hyperpigmentation by patients and by surgeons blinded to the treatment method

Hyperpigmentation improvement	N (%)	
	Surgeon's assessment	Patient's assessment
None (0 %)	–	–
Poor (1–25 %)	–	–
Fair (26–50 %)	3 (8.6)	4 (11.4)
Good (51–75 %)	19 (54.3)	27 (77.1)
Excellent (76–100 %)	13 (37.1)	4 (11.4)

Total: 35 cases

Percentages may total more or less than 100 because of rounding

Results

Thirty-five Asian patients (13 males, 22 females) with a mean age of 23.7 years were enrolled in the study. All patients completed three to five treatments according to the protocol and were included in the final analysis.

All patients were satisfied with their treatment and noticed improvement without serious adverse effects such as infection, hyperpigmentation, hypopigmentation, or worse of scarring. The only complaint was about pain during treatments, with a mean pain score on the visual analog scale of 6.7 ± 0.7 . The facial punctate crusts began to fall off on the fifth day and completely disappeared on the seventh day after each treatment. The mean epithelialization time was 7.0 ± 1.2 days (Table 1).

The patients and the two plastic surgeons rated the improvement of hyperpigmentation at 2 months after the last treatment using the five-point scale described above. According to assessments by the surgeons, the improvement of hyperpigmentation was excellent in 37.1 % of patients (13/35), good in 54.3 % (19/35), fair in 8.6 % (3/35), and poor in 0 % (0/35) (Table 2). The mean score for improvement of hyperpigmentation was 4.28. According to assessments by the

patients, the improvement of hyperpigmentation was excellent in 11.4 % of patients (4/35), good in 77.1 % (27/35), fair in 11.4 % (4/35), and poor in 0 % (0/35) (Table 2). The mean score for improvement of hyperpigmentation was 4. The patients also reported some softening of the scars, despite little improvement in scar appearance. Three representative cases are shown in Figs. 1, 2, and 3.

Discussion

Post-burn facial hyperpigmentation in superficial scars is a constant reminder to patients of the trauma they experienced and often leads to severe psychological suffering. The most commonly used nonsurgical treatments for such hyperpigmentation include topical agents and laser treatment. However, long-term outcomes show that use of topical agents has limited effectiveness, and conventional fractional laser treatment is associated with adverse effects such as hypopigmentation, post-inflammatory hyperpigmentation, and erythema, especially in Asian patients [4–7]. The outcomes after these treatments are also operator dependent.

Micro-plasma radiofrequency technology provides a new treatment modality for facial post-burn hyperpigmentation. The micro-plasma radiofrequency system is a novel device that uses radiofrequency energy to convert nitrogen gas into a grid of high-energy foci of matter called plasma. The plasma causes mild epidermal ablation with rapid re-epithelialization, as well as extensive dermal remodeling, including new collagen synthesis and collagen remodeling. Micro-plasma radiofrequency treatment has been used in clinical studies of the treatment of scars and facial skin rejuvenation [8–12]. Halachmi et al. [8] reported the successful treatment of acne scars and facial rhytids with multiple micro-plasma radiofrequency treatments at 35–50 W, which was well tolerated and had a short recovery time. Wu et al. [14] reported an 83.33 % rate of improvement of facial acne scars after three to five micro-plasma radiofrequency treatments. Higashimori et al. [12] showed that plasma treatment was clinically effective and

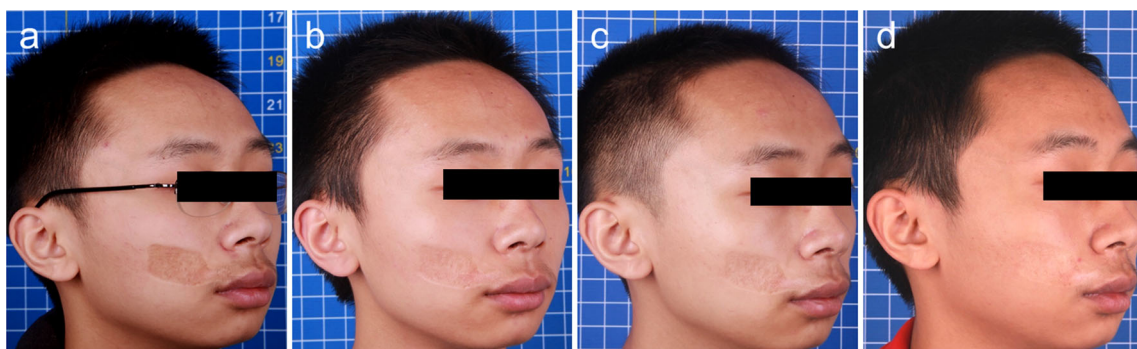

Fig. 1 Micro-plasma radiofrequency treatment (80 W, 3 passes, roller tip) of facial post-burn hyperpigmentation. **a** Before treatment, **b** 2 months after the first treatment, **c** 2 months after the second treatment, and **d** 2 months after the third treatment

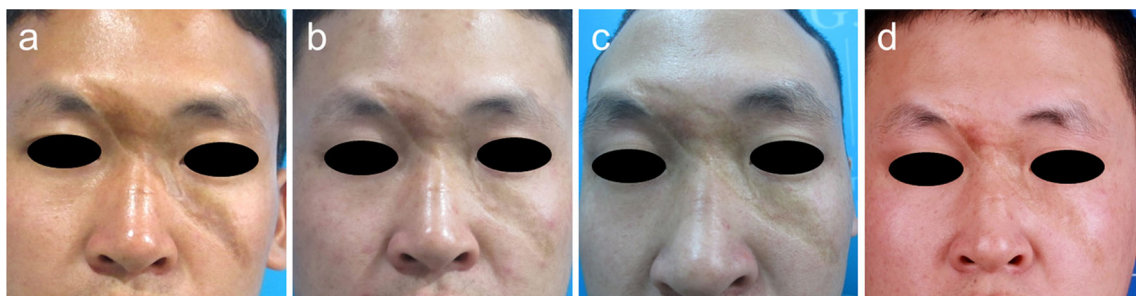


Fig. 2 Micro-plasma radiofrequency treatment (80 W, 3 passes, roller tip) of facial post-burn hyperpigmentation. **a** Before treatment, **b** 2 months after the first treatment, **c** 2 months after the second treatment, and **d** 2 months after the third treatment

was associated with minimal complications when used to treat mesh skin grafted scars in Asian patients.

Micro-plasma radiofrequency treatment of facial post-burn hyperpigmentation has not previously been reported. Our clinical experience shows that 3–5 micro-plasma radiofrequency treatments can result in obvious improvement of hyperpigmentation, with improvement of >51 % in 32 of the 35 patients. Thirteen of these 32 patients achieved excellent improvement without complications. The mean score for improvement of hyperpigmentation was 4.28. Micro-plasma radiofrequency treatment results in delayed mild epidermal ablation and rapid healing [15], and the findings of this study show that it is an effective and safe treatment for post-burn hyperpigmentation. However, the mechanisms underlying improvement of hyperpigmentation, and the effects of this treatment on melanocyte function, are still unclear. It is important to establish a stable and reliable animal model to further investigate this treatment. In addition, the majority of patients reported some softening of the scars after a series of treatments, even though there was no significant improvement in appearance. Administration of a larger number of treatments may further improve the facial scars of some patients.

The micro-plasma radiofrequency device can be used with a roller tip or a stationary tip. The stationary tip is useful when the scar has many peaks and valleys, such as an acne scar. The

roller tip can easily be rotated in different directions, which is convenient for the operator. According to Halachmi et al. [8], the whole face can be treated within 10 min using a roller tip. The roller tip may therefore be more suitable for the treatment of larger burn areas. In contrast to treatment using laser devices, no special protective eyewear is required for either the operator or the patient, as the micro-plasma radiofrequency device produces only tiny sparks. Unlike aggressive ablation techniques, the micro-plasma radiofrequency technique is minimally operator dependent when compared with CO₂ laser treatment and is safe even when used with high energy and when performing double passes [9, 16, 17]. However, operators should receive formal training of plasma treatment and learn how to choose good clinical indications, in order to avoid the occurrence of adverse effects.

In conclusion, our results show that micro-plasma radiofrequency technology is effective and safe for the treatment of post-burn hyperpigmentation in Asian patients. No severe adverse effects were observed when used in patients with Fitzpatrick skin type III or IV. However, this technology has some important limitations. Patients often complained of pain during treatment, and future clinical studies should evaluate methods of alleviating this pain, such as by using a forced cool air chiller before treatment. For those patients with extreme fear in

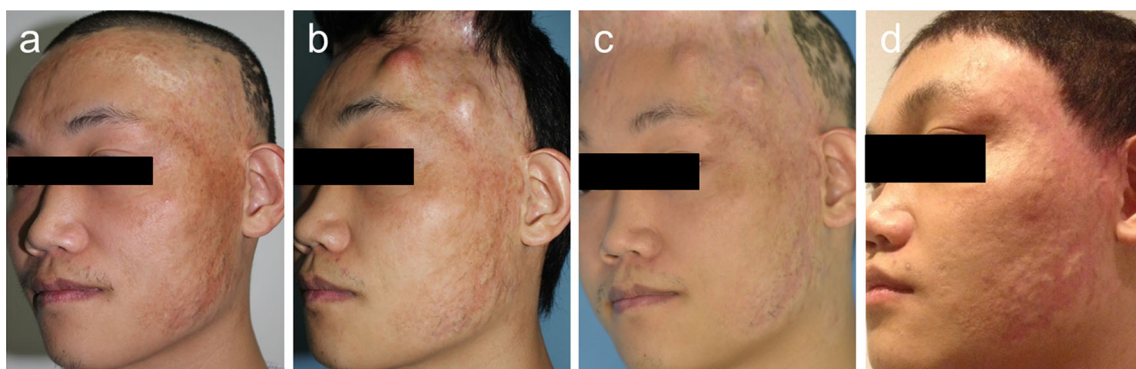


Fig. 3 Micro-plasma radiofrequency treatment (80 W, 4 passes, roller tip) of facial post-burn hyperpigmentation. **a** Before treatment, **b** 2 months after the first treatment, **c** 2 months after the second treatment, and **d** 2 months after the third treatment. This patient also underwent scalp

expansion using a skin expander, forehead scar resection, and scalp expansion skin flap reconstruction for cicatricial alopecia. **b**, **c** Two rounded injection ports on the left forehead

mind, it is better to perform plasma treatment under sedation anesthesia. Patients will finish the treatment in a few minutes of sleep without any pain. Although it increases a certain economic costs, sedation anesthesia is the best way to alleviate the pain. Moreover, although the skin was carefully protected from sun during the treatment period, and it is unknown whether hyperpigmentation will recur in the long term. Further investigation is needed to determine outcomes at 6 months or longer after the final treatment.

Conflicts of interest The authors declare no conflicts of interest.

References

1. Woolery-Lloyd H, Kammer JN (2011) Treatment of hyperpigmentation. *Semin Cutan Med Surg* 30:171–175
2. Alghamdi KM (2010) The use of topical bleaching agents among women: a cross-sectional study of knowledge, attitude and practices. *J Eur Acad Dermatol Venereol* 24:1214–1219
3. Kang HY, Valerio L, Bahadoran P, Ortonne JP (2009) The role of topical retinoids in the treatment of pigmentary disorders: an evidence-based review. *Am J Clin Dermatol* 10:251–260
4. Halachmi S, Haedersdal M, Lapidoth M (2014) Melasma and laser treatment: an evidenced-based analysis. *Lasers Med Sci* 29:589–598
5. Chan NP, Ho SG, Shek SY, Yeung CK, Chan HH (2010) A case series of facial depigmentation associated with low fluence Q-switched 1,064 nm Nd: YAG laser for skin rejuvenation and melasma. *Lasers Surg Med* 42:712–719
6. Chan HH, Manstein D, Yu C, Shek S, Kono T, Wei WI (2007) The prevalence and risk factors of post-inflammatory hyperpigmentation after fractional resurfacing in Asians. *Lasers Surg Med* 39:381–385
7. Nanni CA, Alster TS (1998) Complications of carbon dioxide laser resurfacing. An evaluation of 500 patients. *Dermatol Surg* 24:315–320
8. Halachmi S, Orenstein A, Meneghel T, Lapidoth M (2010) A novel fractional micro-plasma radio-frequency technology for the treatment of facial scars and rhytids: a pilot study. *J Cosmet Laser Ther* 12:208–212
9. Gonzalez MJ, Sturgill WH, Ross EV, Uebelhoer NS (2008) Treatment of acne scars using the plasma skin regeneration (PSR) system. *Lasers Surg Med* 40:124–127
10. Foster KW, Moy RL, Fincher EF (2008) Advances in plasma skin regeneration. *J Cosmet Dermatol* 7:169–179
11. Kono T, Groff WF, Sakurai H, Yamaki T, Soejima K, Nozaki M (2009) Treatment of traumatic scars using plasma skin regeneration (PSR) system. *Lasers Surg Med* 41:128–130
12. Higashimori T, Kono T, Sakurai H, Nakazawa H, Groff WF (2010) Treatment of mesh skin grafted scars using a plasma skin regeneration system. *Plast Surg Int*. doi:10.1155/2010/874348
13. Kawada A (2000) Risk and preventive factors for skin phototype. *J Dermatol Sci* 23:S27–S29
14. Wu XL, Gao Z, Liu K, Xia LL, Bao YF, Ruan J, Liu W (2011) Clinical efficacy of acne scar treatment with micro-plasma radio frequency. *Zhonghua Yi Xue Za Zhi* 91:2604–2606
15. Holcomb JD, Kent KJ, Rousso DE (2009) Nitrogen plasma skin regeneration and aesthetic facial surgery: multicenter evaluation of concurrent treatment. *Arch Facial Plast Surg* 11:184–193
16. Hruza G, Taub AF, Collier SL, Mulholland SR (2009) Skin rejuvenation and wrinkle reduction using a fractional radiofrequency system. *J Drugs Dermatol* 8:259–265
17. Fitzpatrick R, Bernstein E, Iyer S, Brown D, Andrews P, Penny K (2008) A histopathologic evaluation of the plasma skin regeneration system (PSR) versus a standard carbon dioxide resurfacing laser in an animal model. *Lasers Surg Med* 40:93–99